


**PRESENTING CLINICAL SIGNS**

**DATE** History: Surrendered after heart murmur detected. Radiographs showed right heart enlargement/globoid appearance. Asymptomatic.

1/19/23

**ECHOCARDIOGRAPHIC FINDINGS**

2D, M-mode, and Doppler study.

**PERFORMED BY:**

Dr. Meredith Swart

**INTERPRETED BY**

Keith Blass, DVM,  
MS, DACVIM  
(Cardiology)

Left atrial size is normal. The mitral valve is normal. Left ventricular dimensions are normal. Left ventricular systolic function is normal. The aorta and aortic valve appear normal, though there is mildly increased flow velocity in the ascending aorta. There is severe right atrial and right ventricular dilation. The tricuspid valve leaflets are mildly thickened and have shortened chordae tendinae. A severe jet of tricuspid regurgitation is present. TR velocity does not suggest the presence of pulmonary hypertension. The pulmonary artery and pulmonic valve are normal. No shunting lesions are visualized. No pericardial effusion or cardiac masses are seen.

**PATIENT**

Pink Juice Cole VC

LA - 18.0 mm  
LVIDd - 21.3 mm  
LVIDs - 13.7 mm  
FS - 35.7%  
RA - 37.9 mm  
RVIDd - 31.8 mm  
LVOT - 2.14 m/s  
RVOT - 0.94 m/s  
TR - 2.48 m/s

**SPECIES**

Canine

**ASSESSMENT/RECOMMENDATIONS**

Tricuspid valve dysplasia (TVD)

**BREED**

Labrador Retriever

This examination demonstrates severe regurgitation of blood across Pink Juice's tricuspid valve resulting from valvular dysplasia. Secondary to her regurgitation, Pink Juice has severe dilation of both her right atrium and right ventricle. Given this, Pink Juice is at high risk for the development of right-sided congestive heart failure, arrhythmia formation, exercise intolerance, and syncope, therefore, careful monitoring for these is recommended.

**SEX**

FI

I recommend starting Pink Juice on pimobendan (0.25-0.3 mg/kg BID), as this medication may help to slow the progression of her tricuspid valve disease.

**AGE**

10 wk

Surgical repair of tricuspid valve dysplasia has been described in dogs, though there are only a few institutions that perform the procedure. I believe that Colorado State University does, but it's possible that there could be a clinical closer to home that does so, and it may be warranted to contact the closest veterinary teaching hospital to see if they perform the surgery or if they could tell you who does in the region.

**WEIGHT**

14 lb

A recheck echocardiogram is recommended in 6 months. Abdominal radiographs are recommended if Pink Juice develops a distended abdomen, while thoracic radiographs are recommended if she experiences difficulty breathing.

**HOSPITAL NAME**

Swart Veterinary  
Imaging

**REFERRING VET**

Dr. Swart



DATE

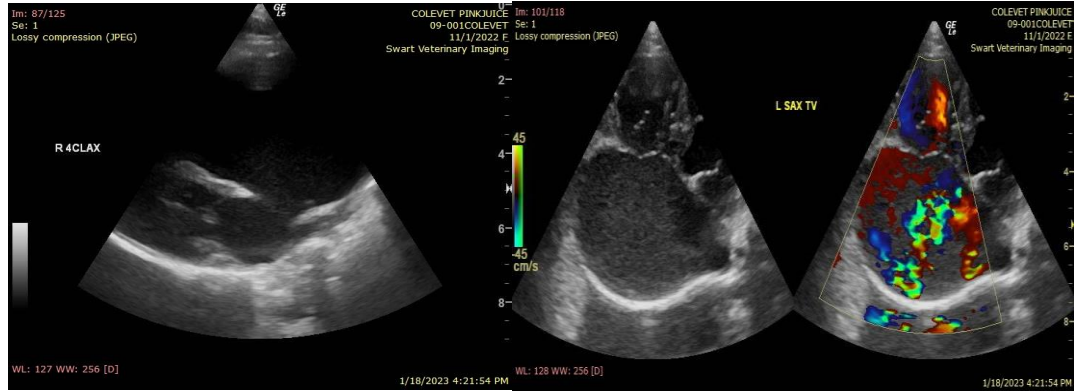
1/19/23

PERFORMED BY:

Dr. Meredith Swart

INTERPRETED BY

Keith Blass, DVM,  
MS, DACVIM  
(Cardiology)



The information and recommendations provided are based on the images presented by the referring veterinarian. No evaluation can be communicated regarding pathology that was not visible in the image/video clips provided.

PATIENT

Pink Juice Cole VC

Thank you for this referral. If the clinical or image interpretation does not parallel your findings or if I can be of any further assistance please contact me.

Keith Blass, DVM, MS, DACVIM (Cardiology)  
KeithBlass@gmail.com  
631-804-5754

SPECIES

Canine

BREED

Labrador Retriever

SEX

FI

AGE

10 wk

WEIGHT

14 lb

HOSPITAL NAME

Swart Veterinary  
Imaging

REFERRING VET

Dr. Swart